



## Multiple lateral sinus pericranii – A case report

### Multipli lateralni perikranijalni sinus

Dražen Ivetić\*, Goran Pavličević\*†, Branislav Antić\*†, Dejan Kostić‡

\*Department of Neurosurgery, ‡Institute of Radiology, Military Medical Academy, Belgrade, Serbia; †Faculty of Medicine of the Military Medical Academy, University of Defence, Belgrade, Serbia

#### Abstract

**Introduction.** Sinus pericranii is a rare vascular anomaly. It is characterized by abnormal communication between the extracranial and intracranial venous system, usually involving the superior sagittal sinus and occasionally the transverse sinus. Off the midline lesions are extremely rare. Multiplicity, associated venous lakes, venous angioma and lateral location are unusual and unique presentation of sinus pericranii. **Case report.** A case of multiple congenital off-midline sinus pericranii in the left frontotemporal and parietal region is presented. Magnetic resonance imaging showed an extracranial vascular anomaly connected with the intracranial venous system through abnormal diploic or emissary veins. The lesions were removed completely by surgery. **Conclusion.** Sinus pericranii is a rare vascular malformation with unique clinical and radiological features. Sinus pericranii may cause fatal complications, and it must be treated by surgical or endovascular procedures.

#### Key words:

sinus pericranii; neurosurgical procedures; diagnosis; treatment outcome.

#### Apstrakt

**Uvod.** Perikranijalni sinus predstavlja veoma retku vaskularnu anomaliju. Karakteriše se patološkom komunikacijom između ekstrakranijalnog i intrakranijalnog venskog sistema, obično komunicira direktno sa gornjim sagitalnim sinusom, a retko sa transverzalnim sinusom. Lateralne pozicije perikranijalnog sinusa su izrazito retke. Multiple promene, prisustvo venskih jezera, venski angiomi i lateralna pozicija predstavljaju neobičnu i jedinstvenu prezentaciju perikranijalnog sinusa. **Prikaz bolesnika.** U radu je prikazan bolesnik sa multiplim kongenitalnim lateralnim perikranijalnim sinusima u levoj čeonoslepočnoj i parijetalnoj regiji. Magnetna rezonanca ukazala je na ekstrakranijalnu vaskularnu anomaliju koja komunicira sa intrakranijalnim venskim sistemom preko diploične ili emisarne vene. Anomalija je u potpunosti odstranjena hirurškom intervencijom. **Zaključak.** Perikranijalni sinus je veoma retka vaskularna malformacija sa karakterističnom kliničkom i radiološkom prezentacijom. Može prouzrokovati veoma ozbiljne komplikacije, zbog čega mora biti rešen hirurškim ili endovaskularnim procedurama.

#### Ključne reči:

perikranijalni sinus; neurohirurške procedure; dijagnoza; lečenje, ishod.

#### Introduction

Sinus pericranii (SP) is a rare vascular anomaly. It is characterized by an abnormal communication between the extracranial and intracranial venous system, usually involving the superior sagittal sinus and occasionally the transverse sinus<sup>1</sup>. Lateral sinus pericranii or sinus pericranii of the transverse sinus is exceedingly rare<sup>1</sup>.

The venous collections receive blood from and drain into the intracranial venous sinuses<sup>2</sup>. Usually, this lesion presents as a soft, fluctuant, painless scalp mass that is easily compressed and more prominent with Valsalva maneuvers. In general, sinus pericranii is considered to be a congenital

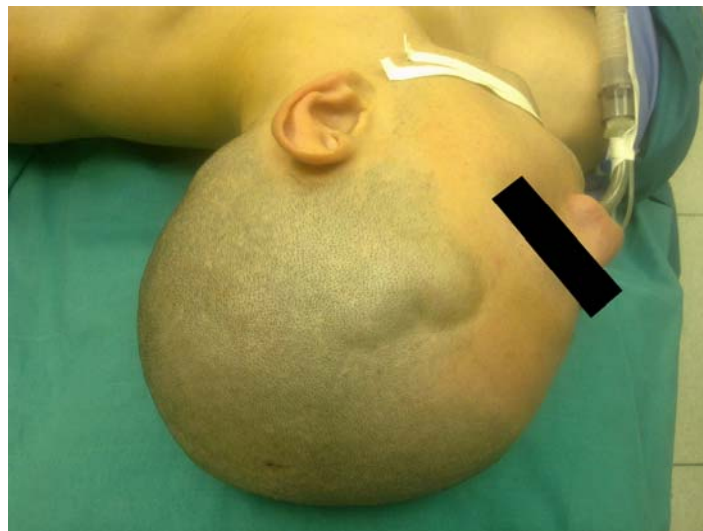
anomaly, but trauma is believed to be a possible causative factor in acquired sinus pericranii<sup>3</sup>. An extremely rare case of multiple congenital and off-midline located sinus pericranii is presented. Multiplicity, associated venous lakes, venous angioma and lateral location are unusual and unique presentation of sinus pericranii<sup>4</sup>.

#### Case report

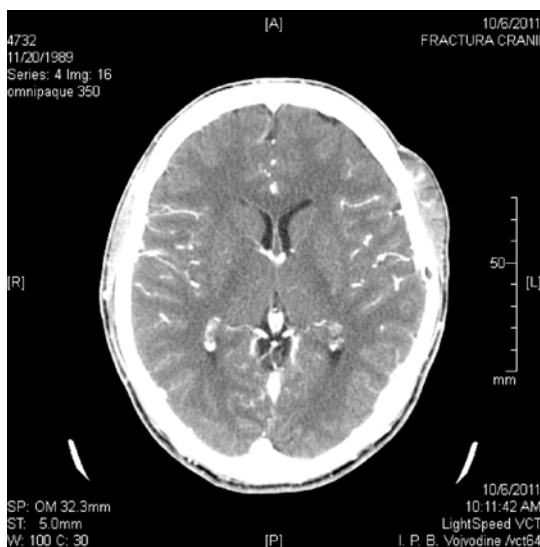
A 22-year-old man presented with a round soft swelling, nontender scalp masses in the left frontotemporal and another mass in the left parietal region of the cranium (Figure 1). The masses presented in early childhood and in-

creased in size in time. On physical examination, there was a large soft scalp mass in the left frontotemporal region, and another mass in the left parietal region. The swelling in the frontotemporal region was larger, dimensions  $48 \times 40 \times 6$  mm, whereas another mass dimensions were  $30 \times 18 \times 3$  mm. Either mass was easily compressible and increased in size on coughing, and other kind of Valsalva maneuvers. The skin over the masses was normal. According to history he had some minor trauma of the cranium during his sport activities, and he registered increasing in size of masses in time. The computed tomography (CT) scan with angiography revealed a soft tissue isodense lesions in frontotemporal and parietal left region of the skull with a focal bony defect and a small transosseus vascular structure were also detected (Figures 2 and 3). The contrast enhanced magnetic resonance (MR) imaging revealed multiple formations with laminar morphology; they had mixed signal intensity on T1-weighted images and appeared hyperintense on T2-weighted and FLAIR images. MR images also detected small transosseus vascular structures which appear like emissary/diploic vein

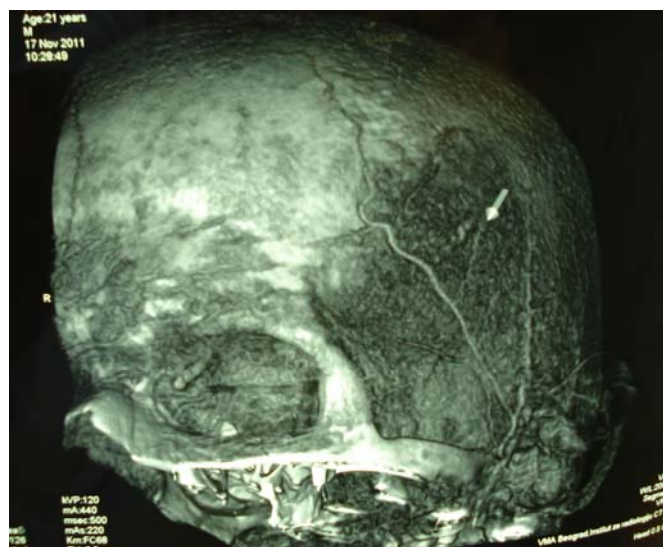and connect extracranial mass with intracranial venous structures, usually with venous sinuses, in our cases with sphenoparietal sinus in frontotemporal located lesion and with intracranial cortical vein and superior sagittal sinus in parietal region (Figures 4 and 5). MR angiography did not detect any other intracranial vascular anomaly. According to the history, physical examination and MR images, we concluded that it was the epicranial vascular venous anomaly of the sinus pericranii type. Due to the risk of future complications the patient elected to undergo surgery. The operation was performed under general anesthesia. The anomaly was resected by soft tissue and emissary vein dissection, without craniectomy, and bone venous channels, including emissary vein, was closed with bone wax (Figures 6 and 7). The same procedure was performed in both anomalies. Histopathology examination was made and cavernous vascular channels with thin vascular endothelium were detected, which is typical for congenital sinus pericranii. Two months after the operation, control MRIs showed a total extirpation of anomalies and no signs for rest and/or recidive of the illness (Figure 8).



**Fig. 1 – Sinus pericranii – round soft swelling scalp mass.**



**Fig. 2 – Computed tomography showing in isointense soft tissue mass.**



**Fig. 3 – Multislice computed tomography (MSCT) angiography with reconstruction revealed a transosseus vessel.**

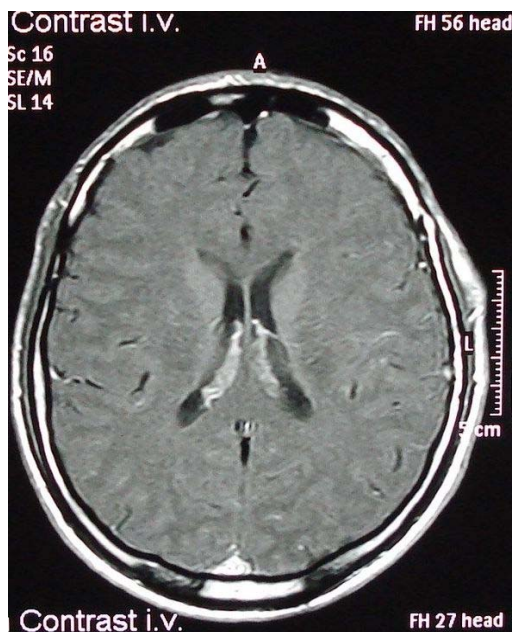


Fig. 4 – Magnetic resonance (MR) image showing the transosseous vessel (emissary or diploic vein) which connects intracranial venous system with extracranial lesion.

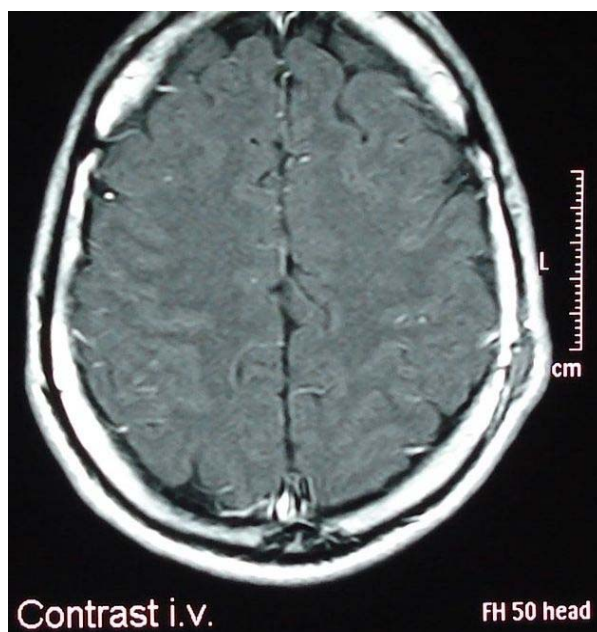


Fig. 5 – Magnetic resonance (MR) image showing sinus pericranii and the transosseous vessel in parietal region.

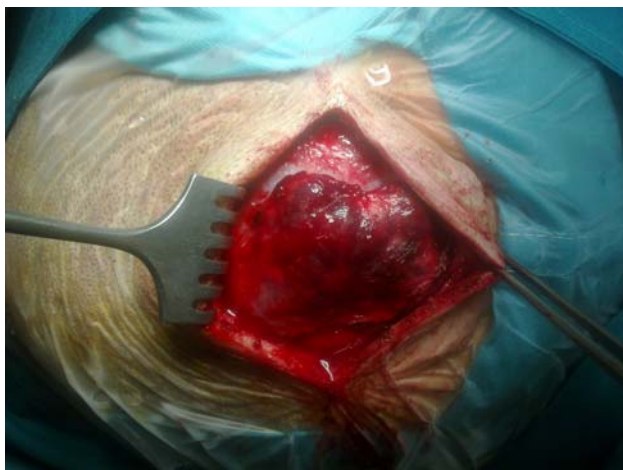


Fig. 6 – Intraoperative picture of large sinus pericranii.

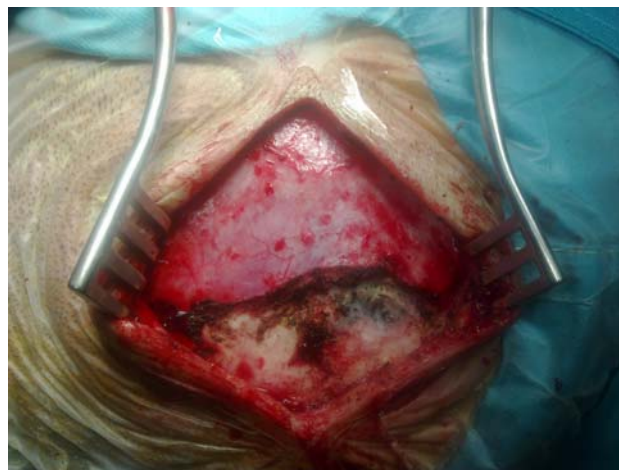

Fig. 7 – Intraoperative picture after removal of sinus pericranii – the bone channel with the emissary vein closed with bone wax.

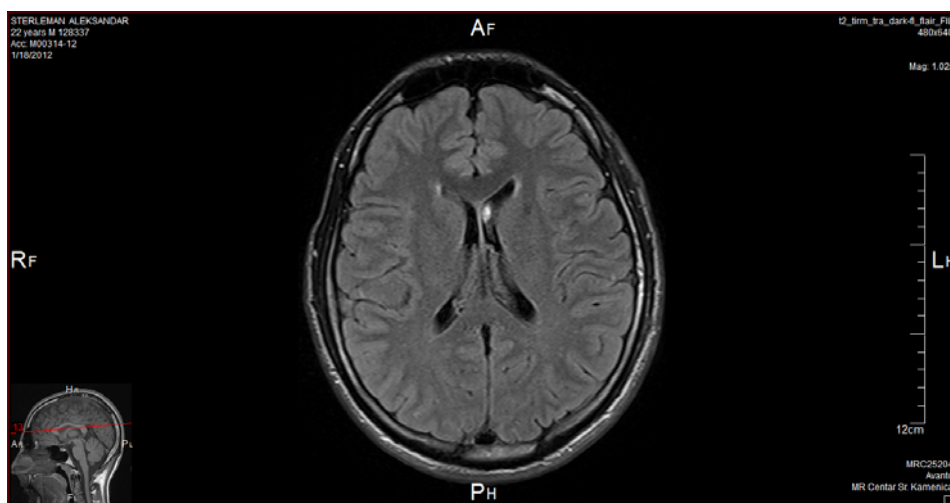


Fig. 8 – Postoperative magnetic resonance (MR) image – total removal of the lesion.



## Discussion

Sinus pericranii was first described by Hecker in 1845 as "varix spurios circumscriptus venae diploicae frontalis"<sup>1</sup>. In 1850, Stromeyer referred this anomaly as a "subperiosteal blood-filled cyst of the skull communicating with an intracranial sinus" and proposed the term "sinus pericranii"<sup>5</sup>. Sinus pericranii is a vascular lesion, consistent with an abnormal transdiploic connection between intracranial and extracranial venous circulation<sup>6</sup>. They usually increase in size on Valsalva manoeuvre and reduce on nondependent position; they disappear with compression<sup>1</sup>. According to Ota et al.<sup>2</sup>, sinus pericranii is a collection of venous blood vessels without tunica muscularis or "venous hemangioma". Sinus pericranii can appear at any age, usually under 30 years, common in males and although usually asymptomatic, may present with nausea, vomiting and vertigo<sup>7,8</sup>. It is most commonly located on the frontal region close to the midline connected to the superior sagittal sinus through a skull defect (Table 1)<sup>6</sup>. Off-midline and multiple lesions are extremely rare. Its multiplicity, association with

flow void, and usually demonstrate the diploic vein which connects intracranial sinus with the abnormal extracranial vessels. Today, according to excellent opportunity of MR imaging and MR angiography, digital subtraction angiography is rarely necessary, except in cases when sinus pericranii is associated with brain vascular anomaly. The differential diagnosis include leptomenigeal cyst, meningocele, encephalocele, epidermoid tumor, cavernous haemangioma, scalp arteriovenous malformation. The diagnosis of sinus pericranii and its differentiation from scalp arteriovenous malformation can be difficult. Strictly speaking, sinus pericranii is a collection of nonmuscular venous blood vessels tightly adhering to the outer surface of the cranium and communicating directly with an intracranial venous sinus<sup>1,12</sup>. Treatment for sinus pericranii has mainly been recommended for cosmetic reasons, prompt treatment after diagnosis is required for prophylactic purposes to prevent complications such as thrombosis, traumatic air embolism or massive hemorrhage<sup>1,11</sup>. Surgery is the usual method of treatment. In surgical treatment, the goal is to resect the extracranial venous package and ligate the emissary communicating vein<sup>11</sup>. This

**The commonest location of the sinus pericranii lesions<sup>6</sup>**

| Location          | Number of cases | Percentage (%) |
|-------------------|-----------------|----------------|
| Frontal           | 46              | 43             |
| Parietal          | 39              | 36             |
| Occipital         | 8               | 7.4            |
| Frontoparietal    | 5               | 4.6            |
| Parieto-occipital | 4               | 3.7            |
| Occipito-temporal | 4               | 3.7            |
| Temporal          | 2               | 1.9            |

**Table 1**

dural venous lakes, and developmental venous anomaly such as a venous angioma, and its peritorcular and lateral location are unique presentation<sup>4</sup>. The pathogenesis and etiology of this peculiar disorder is not definitively known. Mainly congenital, traumatic and spontaneous causes are described for the development of sinus pericranii<sup>8</sup>. Some authors suggest an acquired pathophysiology because of the development of sinus pericranii after head trauma, skull fracture, emissary vein tear, or birth trauma<sup>9,10</sup>. The main difference between spontaneous and traumatic lesions is the presence of endothelial lining. The presence of connective tissue suggests a traumatic origin, whereas the presence of vascular endothelium indicates a congenital or spontaneous origin<sup>11</sup>. Sinus pericranii is usually asymptomatic and the problems are cosmetics. Rarely there may be headache, vertigo and fatal complications such as hemorrhage, thrombosis or air embolism<sup>1,2,11</sup>. The diagnosis of sinus pericranii can be made by the appearance of soft, fluctuant mass located near the intracranial sinus which can vary in size with change in the intracranial pressure. It can be investigated by X-ray, CT scan, MR imaging and/or digital subtraction angiography. MR imaging study with contrast medium administration will demonstrate a soft-tissue mass of mixed signal intensity with the areas of

can be done by craniectomy or by dissection of soft tissue and vein without craniectomy, like in our case. Endovascular treatment using transvenous route and percutaneous direct puncture has also been described<sup>13,14</sup>. Although spontaneous regression of sinus pericranii has been reported, most patients require removal of the sinus and blocking the communicating veins<sup>15-17</sup>.

Sinus pericranii is a rare vascular malformation with unique clinical features. Sinus pericranii may cause fatal complications, and it must be treated by surgical or endovascular procedures. Exceptionally, sinus pericranii may have a prominent role in the venous drainage of the intracranial compartment, and represents the main venous drainage of the underlying brain in case of bilateral occlusion of the jugular veins, and no surgical nor endovascular treatment are recommended<sup>18,19</sup>.

## Conclusion

Sinus pericranii is a rare vascular malformation with unique clinical and radiological features. Sinus pericranii may cause fatal complications, and it must be treated by surgical or endovascular procedures.

## R E F E R E N C E S

1. *Bollar A, Allut AG, Prieto A, Gelabert M, Becerra E.* Sinus pericranii: radiological and etiopathological considerations. Case report. *J Neurosurg* 1992; 77(3): 469–72.
2. *Ota T, Waga S, Handa H, Nishimura S, Mitani T.* Sinus pericranii. *J Neurosurg* 1975; 42(6): 704–12.
3. *Mori K, Yoneda S, Handa H.* Post-traumatic subepicranial varix. *Surg Neurol* 1976; 5(6): 337–9.
4. *Rizvi M, Behari S, Singh RK, Gupta D, Jainal AK, Jain M, et al.* Sinus pericranii with unusual features: multiplicity, associated dural venous lakes and venous anomaly, and a lateral location. *Acta Neurochir (Wien)* 2010; 152(12): 2197–204.
5. *Stromeyer L.* Ueber sinus pericranii. *Dtsch Klin* 1850; 2: 160–1.
6. *Akram H, Prezerakos G, Haliasos N, O'Donovan D, Low H.* Sinus pericranii: an overview and literature review of a rare cranial venous anomaly (a review of the existing literature with case examples). *Neurosurg Rev* 2012; 35(1): 15–26.
7. *Sadler LR, Tarr RW, Jungreis CA, Sekbar L.* Sinus pericranii: CT and MR findings. *J Comput Assist Tomogr* 1990; 14(1): 124–7.
8. *Kamble RB, Venkataramana NK, Naik L, Shetty R.* Sinus pericranii presenting with macrocephaly and mental retardation. *J Pediatr Neurosci* 2010; 5(1): 39–41.
9. *Buxton N, Vloeberghs M.* Sinus pericranii. Report of a case and review of the literature. *Pediatr Neurosurg* 1999; 30(2): 96–9.
10. *Nakasu Y, Nakasu S, Minouchi K, Handa J.* Multiple sinus pericranii with systemic angiomas: case report. *Surg Neurol* 1993; 39(1): 41–5.
11. *Yun DJ, Kim HD, Choi S, Kim SJ.* Sinus pericranii: case report. *Korean J Cerebrovasc Surg* 2011; 13(2): 75–9.
12. *Lanzino G, Passacantilli E, Lemone GM, McDougall C, Spetzler RF.* Scalp arteriovenous malformation draining into the superior sagittal sinus associated with an intracranial arteriovenous malformation: just a coincidence? Case report. *Neurosurgery* 2003; 52(2): 440–3; discussion 443.
13. *Higuchi M, Fujimoto Y, Ikeda H, Kato A.* Sinus pericranii: neuroradiologic findings and clinical management. *Pediatr Neurosurg* 1997; 27(6): 325–8.
14. *Kessler IM, Esmanboto B, Riva R, Mounayer C.* Endovascular transvenous embolization combined with direct puncture of the sinus pericranii. A case report. *Interv Neuroradiol* 2009; 15(4): 429–34.
15. *Desai K, Bhayani R, Goel A, Muzumdar D.* Sinus pericranii in the frontal region: a case report. *Neurol India* 2001; 49(3): 305–7.
16. *Hayakawa I, Fujiwara K, Sasaki A, Hirata T, Yanagibashi K, Tsuchida T.* Spontaneous regression of sinus pericranii - report of a case. *No Shinkei Geka* 1978; 6(1): 91–5. (Japanese)
17. *Carpenter JS, Rosen CL, Bailes JE, Gailloud P.* Sinus pericranii: clinical and imaging findings in two cases of spontaneous partial thrombosis. *Am J Neuroradiol* 2004; 25(1): 121–5.
18. *Frassanito P, Massimi L, Tamburrini G, Caldarelli M, Pedicelli A, di Rocco C.* Occipital sinus pericranii superseding both jugular veins: description of two rare pediatric cases. *Neurosurgery* 2013; 72(6): 1054–8.
19. *Rabeja A, Satyarthee GD, Sharma BS.* Single, small, spontaneous, accessory, closed type, frontal sinus pericranii in a child: favorable outcome with surgical excision. *Neurol India* 2013; 61(6): 680–3.

Received on April 16, 2014.

Revised on June 19, 2014.

Accepted on July 4, 2014.

Online First July, 2015